

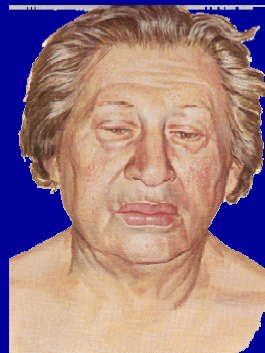
The Cardiac Physical Exam

An assessment of the patient's general appearance may provide important clues to an underlying cardiac diagnosis.

- Head and face
- Eyes
- Skin and Mucous membranes
- Extremities

This patient is likely to have which of the following problems?

- 1. Muscular dystrophy
- 2. Depression
- **3. Hypothyroidism**
- 4. Lung cancer
- 5. Rheumatoid arthritis

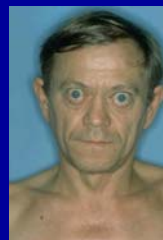
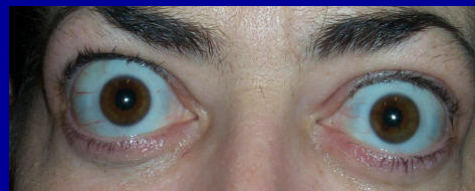
The Cardiac Physical Exam

- **Myxedema** (hypothyroidism) is characterized by a dull, expressionless face, periorbital puffiness, loss of the lateral eyebrows and dry, sparse hair.
- The tongue is large.
- The patients will complain of cold intolerance, dry skin, hoarseness, constipation, and shortness of breath.

**These patients present with heart failure.
Which endocrine disorder do they have?**

1. Hypothyroidism
2. **Hyperthyroidism**
3. Cushing's syndrome
4. Addison's disease
5. Acromegaly

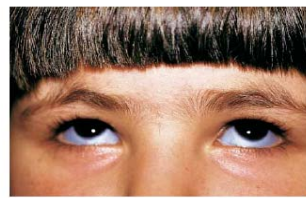
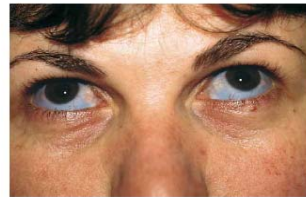
The Cardiac Physical Exam

- **Exophthalmos** and stare occur in hyperthyroidism which can cause heart failure in a patient with reduced cardiac reserve.
- Severe tricuspid regurgitation can cause pulsatile exophthalmos (as well as pulsation of the earlobes).

This mother and daughter have blue sclerae which can be seen in which of the following disorders?

- 1. Marfan syndrome
- 2. Rheumatoid arthritis
- 3. **Osteogenesis imperfecta**
- 4. Cystic Fibrosis
- 5. Muscular dystrophy



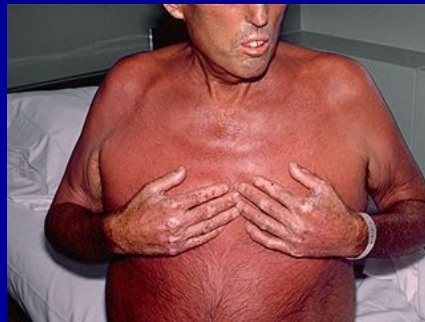The Cardiac Physical Exam

Osteogenesis Imperfecta

- A connective tissue disorder associated with fragile bones (fractures with minimal trauma), blue sclerae, and aortic root dilatation, aortic regurgitation, and mitral valve prolapse.

This patient presents with shortness of breath and diabetes. What is the most likely diagnosis?

1. Too much time in Florida
2. Acromegaly
3. Amyloidosis
4. **Hemochromatosis**
5. Cirrhosis

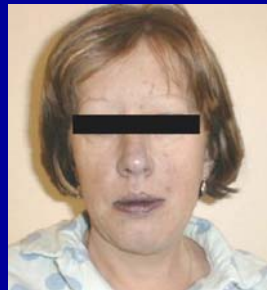

The Cardiac Physical Exam

Hemochromatosis is a hereditary disorder in which the small intestine absorbs excessive iron. The excess is stored in glands and muscle such as the liver, pancreas and the heart. Iron deposition in the heart causes a restrictive cardiomyopathy, leading to congestive heart failure. It is seen much more commonly in men than in women (8:1 ratio).

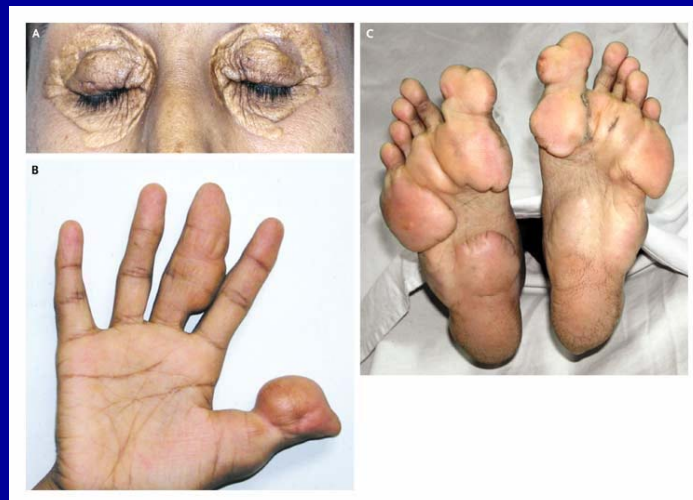This patient has reduced exercise tolerance. You suspect which of the following cardiac abnormalities?

- 1. left to right intracardiac shunt
- **2. right to left intracardiac shunt**
- 3. rheumatic fever
- 4. mitral valve prolapse
- 5. endocarditis



The Cardiac Physical Exam

- This patient has **central cyanosis** which is due to intracardiac or intrapulmonary right-to-left shunting and which involves the entire body including warm, well-perfused areas such as the conjunctivae and the mucous membranes of the oral cavity.
- **Peripheral cyanosis** due to reduction of peripheral blood flow such as occurs in heart failure and peripheral vascular disease is characteristically more prominent in cool, exposed areas that may not be well perfused such as the extremities, particularly the nailbeds.



Girish, M.P. et al. N Engl J Med 2005;352:2424

This patient is a 40 year old woman. What is the most likely diagnosis?

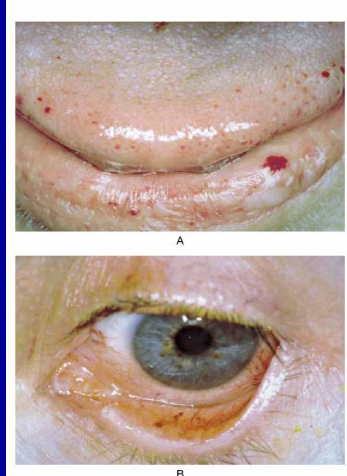
- 1. Gout
- 2. Rheumatoid arthritis
- 3. Lupus
- 4. **Coronary artery disease**
- 5. Leprosy

The Cardiac Physical Exam

This patient has **familial hypercholesterolemia** and has severe coronary artery disease. Physical exam is notable for marked **xanthomas**. **Xanthomas** are an important manifestation of altered lipid metabolism. They are small, firm, painless nodules of a reddish yellow color that can coalesce to form multilobulated tumors. They usually develop in pressure areas and are associated with increased levels of LDL cholesterol.

This patient presents with gastrointestinal bleeding. The patient appears to have central cyanosis. This is most likely caused by?

- 1. Congestive heart failure
- 2. COPD
- 3. **Pulmonary arteriovenous fistulas**
- 4. Cystic fibrosis
- 5. Pulmonary emboli

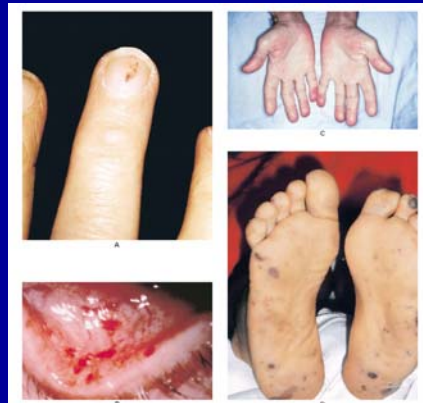

The Cardiac Physical Exam

Hereditary hemorrhagic telangiectasia (Osler-Weber-Rendu syndrome) is a disorder of the vascular structures involving the nose, skin, brain, gastrointestinal tract and lung. Telangiectasias are focal dilatations of the postcapillary venules. Arteriovenous malformations affect the brain (subarachnoid hemorrhage), GI tract (GI bleeding) and lung (causing right to left shunts and central cyanosis).

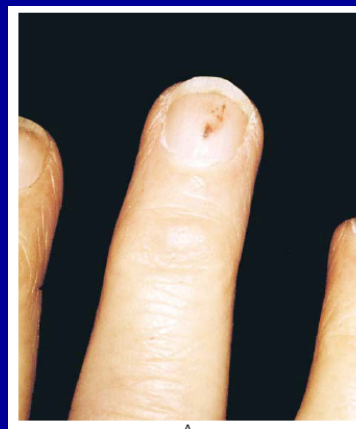A patient with these skin lesions is likely to have which of the following conditions?

- 1. Lupus
- 2. Rheumatoid arthritis
- 3. Leprosy
- 4. **Endocarditis**
- 5. Melanoma



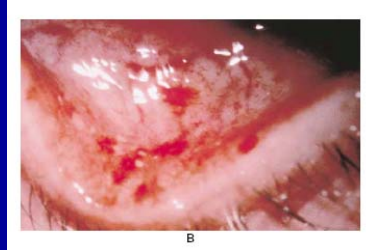
The Cardiac Physical Exam

Panel A shows splinter hemorrhages which are normally seen under the fingernails or toenails. They are usually linear and red for the first two to three days and brownish thereafter.

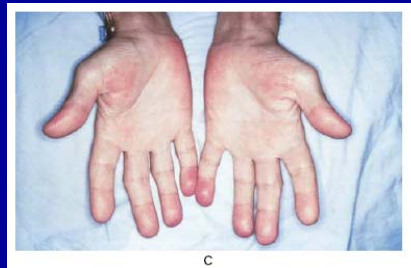

The Cardiac Physical Exam

Panel B shows conjunctival petechiae

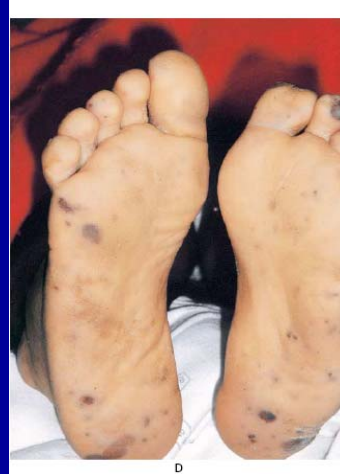

Panel C shows Osler's nodes which are tender, subcutaneous nodules, often in the pulp of the digits or the thenar eminence.



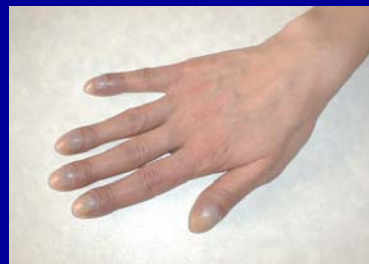The Cardiac Physical Exam

Panel D shows Janeway's lesions which are nontender erythematous, hemorrhagic or pustular lesions, often on the palms or soles.



This patient has cyanosis and CLUBBING. She most likely has which of the following?

1. A very active social life
2. **Cyanotic congenital heart disease**
3. Cystic fibrosis
4. Lupus
5. Rheumatic fever

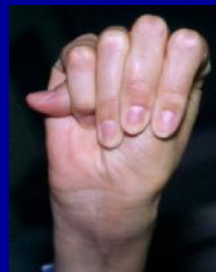

The Cardiac Physical Exam

- **Clubbing** of the digits is characteristic of cyanotic congenital heart disease or pulmonary disease with hypoxia. It may also occur within a couple of weeks of the development of endocarditis. Clubbing is characterized by the loss of the normal angle between the base of the nail and the skin.

The patient who can do the following maneuver is likely to have which of the following conditions?

- 1 Hyperthyroidism
- 2 **Marfan syndrome**
- 3 Rheumatic Heart disease
- 4. Rheumatoid Arthritis
- 5. Lupus



The Cardiac Physical Exam

Marfan syndrome – a connective tissue disorder characterized by:

Skeleton: joint hypermobility, tall stature, arachnodactyly, chest deformities

Eye: retinal detachment

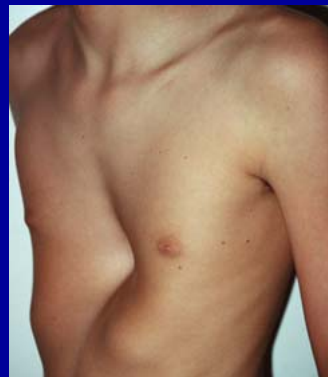Cardiovascular: mitral valve prolapse, dilatation of the aortic root, aortic dissection

Pulmonary: spontaneous pneumothorax

Skin: inguinal hernias

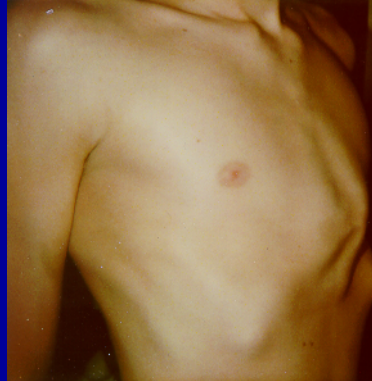The Cardiac Physical Exam

Pectus excavatum (funnel chest), a condition in which the sternum is displaced posteriorly, is commonly observed in Marfan syndrome, homocystinuria, Ehler-Danlos syndrome, and a small percentage of patients with mitral valve prolapse. Rarely there can be significant compression of the heart and elevation of intracardiac pressures.



The Cardiac Physical Exam

Pectus carinatum
(pigeon breast) is often found in patients with Marfan syndrome. It does not directly affect cardiovascular function.



- CD Rom

A “standard” blood pressure cuff can be used on all patients?

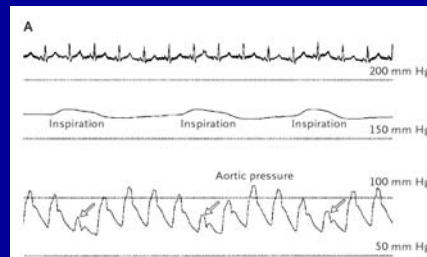
- 1. True
- 2. **False**

The Cardiac Physical Exam

When a standard size cuff is applied to a larger upper arm, arterial pressure is **overestimated** and when applied to a small arm, the pressure is **underestimated**.

An exaggerated fall in arterial blood pressure with inspiration is called?

- 1. Pulsus alternans
- 2. Pulsus bigeminus
- 3. **Pulsus paradoxus**
- 4. Bisferiens pulse



The Cardiac Physical Exam

Pulsus Paradoxus is an exaggerated reduction (more than 10 mmHg during quiet breathing) in the strength of the arterial pulse during normal inspiration due to an exaggerated inspiratory fall in blood pressure. It is a frequent, often “characteristic” finding in patients with cardiac tamponade but can be seen in patients with constrictive pericarditis, pulmonary disease (emphysema and bronchial asthma), hypovolemic shock, pulmonary embolism, and extreme obesity.

If tachycardia makes the identification of S1 difficult, the palpation of which pulse should be used for timing?

- 1. brachial
- 2. radial
- 3. femoral
- 4. **carotid**
- 5. dorsalis pedis

The first heart sound S1 is typically made up of two audible components.

- 1. True
- 2. **False**

The second heart sound S2 is typically made up of two audible components

- 1. True
- 2. False

The second heart sound S2 normally splits on inspiration and is single on expiration

- 1. True
- 2. False

“Fixed” splitting of S2 classically occurs in which of the following conditions?

- 1. Pulmonary hypertension
- **2. Atrial septal defect**
- 3. Ventricular septal defect
- 4. Mitral regurgitation
- 5. Aortic stenosis

The pulmonic (P) component of S2 is usually softer than the aortic (A) component and is heard only in the pulmonic area except in the following condition where P2 is loud and heard more diffusely?

- 1. Pulmonic stenosis
- **2. Pulmonary hypertension**
- 3. Aortic stenosis
- 4. Systemic Hypertension
- 5. Atrial septal defect

“Paradoxical” splitting of S2 (on expiration) occurs when A2 is delayed because of late left ventricular activation. All of the following can delay LV activation except:

- 1. Left-sided congestive heart failure
- 2. Left bundle branch block
- 3. Severe aortic stenosis
- **4. Atrial septal defect**
- 5. Pacing (always from RV apex)

The Cardiac Physical Exam

- CD-ROM

An S4 gallop would be heard before or after the carotid upstroke?

- 1. Before
- 2. After

The Cardiac Physical Exam

An **S4 gallop** (an atrial filling sound) is always abnormal in a 20 year old.

- 1. True
- 2. False

The Cardiac Physical Exam

An **S4 gallop** (atrial filling sound) may be normal in individuals over the age of 50.

- 1. True
- 2. False

An **S3 gallop** (ventricular filling sound) can be a normal finding in individuals under the age of 30.

- 1. True
- 2. False

- CD-ROM

**Sounds heard in systole include
all of the following except?**

- 1. Opening snap
- 2. Aortic ejection click
- 3. Pulmonic ejection click
- 4. Mitral click
- 5. Tricuspid click

Mitral stenosis is most commonly caused by rheumatic fever. Which sound would you most likely hear in a patient with this diagnosis who is in atrial fibrillation?

- 1. Mitral click
- 2. S3 gallop
- 3. Pericardial knock
- 4. **Opening snap**
- 5. S4 gallop

- CD ROM

Murmur intensity or loudness is “graded” using which of the following grading systems?

- 1. A thru D
- 2. Grade I-IV
- 3. Grade 1-V
- 4. **Grade I-VI**

The Cardiac Physical Exam

A **murmur** is a series of auditory vibrations that are more prolonged than a sound and are characterized according to timing in the cardiac cycle (systolic, diastolic, continuous), intensity/loudness, frequency (pitch), duration and shape, and direction of radiation.

The Cardiac Physical Exam

- Grade 1 - so faint that it is only heard with special effort
- Grade 2 – soft but readily detected
- Grade 3 – prominent but not loud
- Grade 4 – loud and usually accompanied by a thrill (palpable sensation on the chest)
- Grade 5 – very loud
- Grade 6 – loud enough to be heard with the stethoscope just removed from contact with the chest wall

A murmur always indicates cardiac disease

- 1. True
- 2. **False**

The Cardiac Physical Exam

In general, diastolic murmurs and continuous murmurs are indicative of disease. Soft systolic murmurs can be normal (eg, the pulmonic flow murmur) in children and in high output states (anemia, fever, thyroid disease, etc).

- CD-ROM

The Cardiac Physical Exam

- It takes a lot of practice to do a good cardiac exam. Use every opportunity you get to improve your physical diagnosis skills.